A Rare Cause of Cardiac Tamponade: Hypereosinophilic Syndrome

KWOK-LEUNG WU, KIN-LAM TSUI, KA-LAI LEE, SUNG-YU LIU, KWOK-KEUNG CHAN, SHU-KIN LI

From Department of Medicine, Pamela Youde Nethersole Eastern Hospital, Hong Kong

WU ET AL.: ***A Rare Cause of Cardiac Tamponade: Hypereosinophilic Syndrome*****.** We describe a male adult patient who presented with chest discomfort and shortness of breath. A diagnosis of cardiac tamponade was made by transthoracic echocardiogram. Urgent pericardiocentesis was performed and analysis of pericardial fluid showed presence of eosinophil. Complete blood picture showed peripheral eosinphilia as well. Subsequent work up for eosinophilia showed ova of Clonorchis sinesis from the stool thus a course of praziquantel was given. Transient clinical improvement and lowering of eosinophil count were observed but two weeks later he developed acute coronary syndrome. Urgent coronary angiogram showed coronary vasospasm. Endomyocardial biopsy was performed afterwards which showed marked eosinophilic infiltrate. Bone marrow biopsy and skin biopsy showed marked marrow eosinophilia and leucocytoclastic vasculitis with abundant eosinophils, respectively. A diagnosis of hypereosinophilic syndrome was made after exclusion of secondary and clonal eosinophilia. After oral steroid was given, his condition was stabilized and the eosinophil count was normalized. *(J HK Coll Cardiol 2012;20:38-42)*

Cardiac tamponade, Hypereosinophilic syndrome, perimyocarditis, prednisolone, vasospasm

摘要

我們描述一位臨床表現爲胸痛和呼吸短促的成年男性病人。經胸廓的超聲心動圖診斷爲急性心包塡塞。緊急施行心包穿刺術，心包積液分析存在嗜酸性粒細胞。全血塗片檢查顯示外周嗜酸性粒細胞也異常增高。爲尋找嗜酸性粒細胞增多的病因，隨後的工作發現糞便中有華支睾吸蟲的蟲卵，因此給與吡喹酮治療。病人獲得短暫的臨床改善和嗜酸性粒細胞計數降低，但兩周後進展爲急性冠脈綜合徵。緊急施行冠狀動脈造影顯示冠狀動脈痙攣。心內膜心肌活檢呈明顯的嗜酸性粒細胞浸潤。骨髓和皮膚活檢分別顯示明顯的骨髓嗜酸性粒細胞增多和富含嗜酸性粒細胞的白細胞碎裂性血管炎。排除繼發性和克隆性嗜酸性粒細胞增多後，診斷爲嗜酸性細胞增多綜合徵。給與口服類固醇治療後，患者病情得到穩定，嗜酸性粒細胞計數也回歸正常。

關鍵詞：心臟塡塞，嗜酸粒細胞增多綜合徵，心包心肌炎，氫化潑尼松，血管痙攣

Introduction

Hypereosinophilic syndrome (HES) is a rare entity characterized by overproduction of eosinophils resulting in end-organ damage. We report a case of HES presented with cardiac tamponade, impaired left ventricular systolic function and acute coronary syndrome due to vasospasm. The case illustrates the diagnostic and treatment approach to this condition. It also illustrates the dilemma in management when the patient was also diagnosed to have coexisting Clonorchiasis as an alternative cause of eosinophilia.

Case Report

A 51-year-old gentleman, who had history of asthma, presented with chest pain for 2 days. On arrival to the casualty department his blood pressure was 75/50 mmHg, pulse 120 bpm, and the oxygen saturation

Address for reprints: Dr. Kwok-Leung Wu
Department of Medicine, Pamela Youde Nethersole Eastern Hospital, 3 Lok Man Road, Chai Wan, Hong Kong

Email: wukwokleung@hotmail.com

Received September 12, 2012; revision accepted September 29, 2012

was 97% while on 4 Litre oxygen. Electrocardiogram (Figure 1) showed sinus tachycardia 112 bpm. Chest X-Ray showed cardiomegaly. Dopamine infusion was given. Blood result showed total white cell count $13.1x10^9$/L, neutrophil count $4.6x10^9$/L, lymphocyte count $1.5x10^9$/L and eosinophil count $6.2x10^9$/L (47.6% of total white cell count). Echocardiogram demonstrated mildly depressed left ventricular systolic function with left ventricular ejection fraction around 40%, and pericardial effusion with signs of cardiac tamponade. Urgent pericardiocentesis was performed. The chest pain subsided and the hemodynamic status was stabilized afterwards.

Echocardiogram was repeated on the next day which showed moderately impaired left ventricular systolic function and the left ventricular ejection fraction measured around 40%. Mild tricuspid regurgitation was noted. No pericardial effusion was detected. Analysis of pericardial fluid revealed presence of eosinophil. A review of the patient's previous admission record showed that his eosinophil count was already raised ($3.7x10^9$/L) seven months before this admission, when he was admitted for an asthmatic attack. Further workup for eosinophilia was performed, which included checking of autoimmune markers (including anti-neutrophil cytoplasmic antibody) and tumor markers. All these results were negative. Stool was saved for parasites. Nerve conduction study was performed because he complaint of occasional numbness over bilateral lower limbs, which showed no evidence of vasculitic polyneuropathy. High resolution computer tomography of thorax showed only non-specific ground glass densities. Subsequently the stool culture yielded ova of Clonorchis sinesis. A course of oral praziquantel was given. Empirical steroid therapy was not started because of proven parasitic infection. Before discharge his eosinophil count was slightly lowered from 6.2 to $5.1x10^9$/L (46.7% of total white cell count).

Two weeks later this gentlemen presented to the casualty department again for chest pain. Electrocardiogram showed ST segment depression over the chest leads V4-6. Serum troponin level was elevated up to 0.16 ng/dL. Total white cell count was $16.9x10^9$/L and eosinophil count was $8.3x10^9$/L (49.1%). A diagnosis of acute coronary syndrome was made. Urgent coronary angiogram (Figure 2) revealed coronary vasospasm over the posterolateral artery and right posterior descending artery, which was relieved by intracoronary nitrate and verapamil injection.

Endomyocardial biopsy was performed several days later in view of persistent peripheral eosinophilia, which showed myocarditis associated with marked

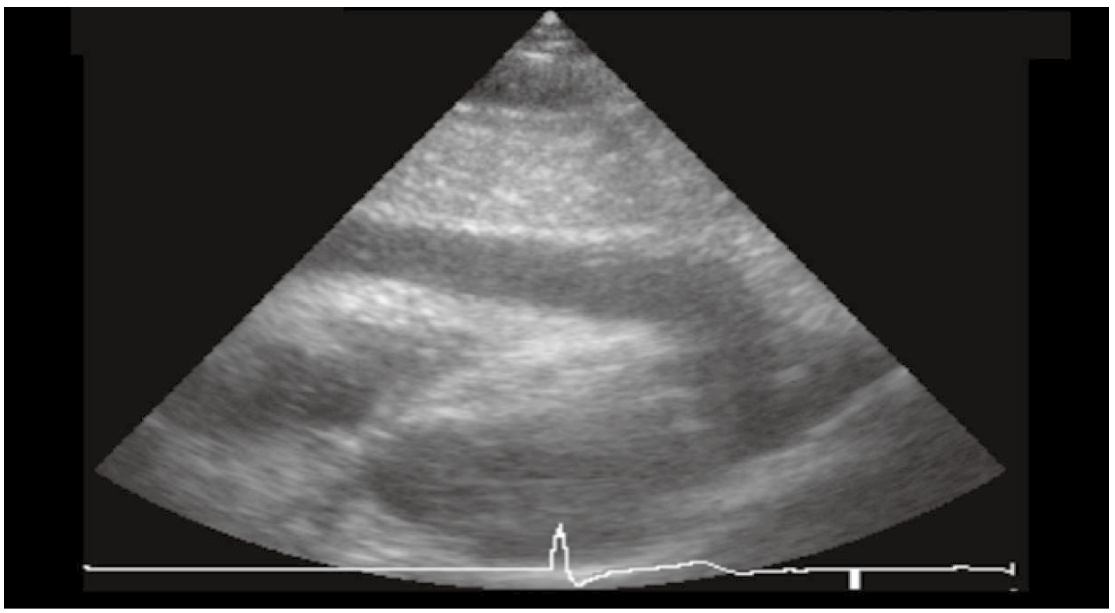

Figure 1. *Echocardiographic finding of pericardial effusion.*

eosinophilic infiltrate. Bone marrow aspiration and trephine biopsy demonstrated marked marrow eosinophilia. During admission this patient was noted to have patchy erythematous rash with sharp demarcation over bilateral lower limbs. Skin biopsy showed leucocytoclastic vasculitis with marked eosinophilic infiltrate. Stool culture was repeated which showed no growth. The diagnosis of hypereosinophilic syndrome was made. Blood for RT-PCR FIP1L1-PDGRFα fusion (reverse transcription polymerase chain reaction for the fusion of Fip1-like gene and platelet-derived growth factor receptor alpha) was checked which was negative.

Oral prednisolone 60 mg per day was then given. The eosinophil count was normalized after several days. Cardiac magnetic resonance imaging (MRI) was performed before discharge which revealed moderately impaired left ventricular systolic function (left ventricular ejection fraction was 36.1%). There was also diffuse scarring in the ventricular wall which suggested cardiac involvement in HES. During follow up he remained asymptomatic and the eosinophil count remained normal. Oral prednisolone was tailed down to 5 mg daily and the plan was to keep this dosage for longer period of time. Follow up cardiac MRI at 4 months after discharge showed improvement in left ventricular systolic function and moderate resolution of myocardial scarring.

Discussion

This patient presented with cardiac tamponade, impaired left ventricular systolic function and acute coronary syndrome due to coronary vasospasm. All these features could be explained by acute eosinophilic myocarditis which was proven by endomyocardial biopsy. Peripheral eosinophilia was noted and several end organs were involved. Eosinophilia can be categorized into secondary (caused by parasitic infestations, vasculitis, drug and lymphoma), clonal (presence of histological, cytogenetic, or molecular evidence of underlying myeloid malignancy) an idiopathic (such as HES) types.[1] It is essential to identify the type of eosinophilia because subsequent management may be very different. Hypereosinophilic syndrome, a subcategory of idiopathic eosinophilia, is defined by the presence of a peripheral blood eosinophil count of 1.5×10^9/L or greater for at least 6 months, exclusion of both secondary and clonal eosinophilia and

Figure 2. *Coronary angiogram showed coronary vasospasm over the posterolateral artery and right posterior descending artery (left panel), which was relieved by intracoronary nitrate and verapamil injection (right panel).*

evidence of end organ involvement.

In this case a secondary cause for eosinophilia was present, which was infestation by Clonorchiasis. This posed diagnostic and treatment dilemma and rendered steroid therapy inappropriate in the initial status. However, as HES carries high morbidity and mortality, treatment by systemic steroid or immunosuppressive agents should be initiated once the infestation was cleared. In this case despite initiation of praziquantel, the patient developed recurrent symptom with rebound of the eosinophil count. During the second admission stool culture was negative. In fact peripheral eosinophilia in Clonorchiasis seldom exceeds 10 to 20% and the infestation is primarily, if not exclusively, confined to the hepatobiliary system. The eosinophil count was around 40% of total white cell count in this case. Multi-organ involvement was proven by histological analysis. This implied that infestation by Clonorchiasis was only a clinical bystander in this case.

Apart from the bronchodilators and the inhaled corticosteroid, this patient did not take other medications. Hematological malignancy was excluded by the bone marrow examination. Another important differential diagnosis in this case was vasculitis, especially Churg-Strauss syndrome (CSS). This case did not completely fulfill the classification criteria of CSS, because it only fitted into 3 (1st, 2nd and 5th) out of 6 criteria by the American College of Rheumatology (need to fulfill 4 out of 6 criteria): 1) Asthma; 2) Eosinophil >10%; 3) Mono/polyneuropathy; 4) Paranasal sinus pathology; 5) Histological proof of eosinophils in extracellular space; 6) Migratory pulmonary opacities.[2] On the other hand, anti-neutrophil cytoplasmic antibody (ANCA) was negative in this case which render the diagnosis of CSS less likely.

This patient had a peripheral blood eosinophil count greater than 1.5×10^9/L for longer than 6 months. There was evidence of multi-organ involvement as well, manifested as acute eosinophilic myocarditis, eosinophilic bone marrow infiltrate and leucocytoclastic vasculitis. Secondary and clonal eosinophilia were less likely in this case. Therefore the most likely diagnosis was HES.

Cardiac involvement is a major cause of morbidity and mortality among patients with HES.[3] Cardiac involvement usually presented as intra-cardiac thrombus formation and endomyocardial fibrosis causing restrictive cardiomyopathy. Cardiac magnetic resonance imaging (MRI) and echocardiography are able to detect fibrosis, eosinophilic infiltrate and thrombi to stage the fibrotic evolution of the disease. Treatment for heart failure, anticoagulation, immunosuppressive therapy are the mainstay of management. The 5-year mortality is estimated to be 30%.[4] Loeffler's endocarditis is a separate entity from HES.[5] However, effects of eosinophils on the heart may go through different stages of initial necrotic phase with intense myocarditis, and associated arteritis (Loeffler's endocarditis) followed by thrombotic stage and finally endomyocardial fibrosis.

Pericardial involvement as in this case, is rare in HES. In retrospect, pericardial or endomyocardial biopsy should be considered during the initial presentation, in order to start timely therapy. Spiegel et al[6] reported a case of eosinophilic pericarditis of an 18-month-old child who presented with eosinophilic pericarditis causing cardiac tamponade requiring pericardiocentesis. The child recovered after prolonged systemic steroid therapy. Tan and Duggal[7] also reported a case with similar scenario in a 56-year-old female. Although coronary vasospasm could occur in HES, in this case the ST change and modest rise in troponin could be accounted by eosinophilic cardiomyopathy alone, and coronary vasospasm was only a laboratory phenomenon. It was because one should expect ST elevation in case of coronary vasospasm, instead of ST depression in this case. Takahashi et al reported a case of acute myocardial infarction in a young man with history of HES. Coronary angiogram was performed which showed vasospasm over the left anterior descending artery.[8] The mechanism by which eosinophils induce coronary spasm could be related to massive infiltration of eosinophils into endomyocardium and the deposition of their granular proteins (such as eosinophilic cationic protein) which may increase vascular tone or irritability.[9]

Bone marrow biopsy is important to exclude secondary eosinophilia due to lymphoma, clonal eosinophilia and the malignant variants of HES, the

myeloproliferative variants and lymphocytic variants.[10] Peripheral blood test for RT-PCR FIP1L1-PDGRFα fusion was negative in our patient. A proportion of patients with HES have an interstitial deletion on chromosome 4q12 resulting in the fusion of two genes, FIP1L1 and PDGFRα. Its presence indicates higher likelihood of potentially fatal cardiac involvement. Moreover, this group of patients will have response to imatinib, a tyrosine kinase inhibitor.[11] In such case imatinib instead of steroid therapy should be started as soon as possible to avoid rapid disease progression.

During follow up, features of end organ involvement, thromboembolism and side effects arising from steroid therapy should be looked for, and eosinophil count should be monitored. Follow up echocardiography and cardiac MRI are recommended as well. For those on imatinib therapy, regular monitoring of left ventricular systolic function is necessary because it is known to cause left ventricular systolic dysfunction.[12]

Conclusion

In summary, we reported a case of hypereosinophilic syndrome with multiple cardiac involvements. Apart from urgent pericardiocentesis to relieve cardiac tamponade, recognition of this rare disease entity, exclusion of secondary and clonal eosinophilia, and appropriate steroid therapy is essential for management of this potentially life-threatening condition.

References

1. Tefferi A, Gotlib J, Pardanani A. Hypereosinophilic syndrome and clonal eosinophilia: point-of-care diagnostic algorithm and treatment update. Mayo Clin Proc 2010;85:158-64.
2. Masi AT, Hunder GG, Lie JT, et al. The American College of Rheumatology 1990 criteria for the classification of Churg-Strauss syndrome (allergic granulomatosis and angiitis). Arthritis Rheum 1990;33:1094-100.
3. Ogbogu PU, Rosing DR, Horne MK 3rd. Cardiovascular manifestations of hypereosinophilic syndromes. Immunol Allergy Clin North Am 2007;27:457-75.
4. Kleinfeldt T, Nienaber CA, Kische S, et al. Cardiac manifestation of the hypereosinophilic syndrome: new insights. Clin Res Cardiol 2010;99:419-27. Epub 2010 Mar 24.
5. Corssmit EP, Trip MD, Durrer JD. Loffler's endomyocarditis in the idiopathic hypereosinophilic syndrome. Cardiology 1999; 91:272-6.
6. Spiegel R, Miron D, Fink D, et al. Eosinophilic pericarditis: a rare complication of idiopathic hypereosinophilic syndrome in a child. Pediatr Cardiol 2004;25:690-2.
7. Tan SA, Duggal A. Pericardial involvement as a rare manifestation of hypereosinophilic syndrome. South Med J 2009;102:751-3.
8. Takahashi N, Kondo K, Aoyagi J. Acute myocardial infarction associated with hypereosinophilic syndrome in a young man. Jpn Circ J 1997;61:803-6.
9. Hertzman PA, Maddoux GL, Sternberg EM, et al. Repeated coronary spasm in a young women with eosinophilia-myalgia syndrome. JAMA 1992 267:2932-4.
10. Gleich GJ, Leiferman KM. The hypereosinophilic syndromes: current concepts and treatments. Br J Haematol 2009;145:271-85.
11. Cools J, DeAngelo DJ, Gotlib J, et al. A tyrosine kinase created by fusion of the PDGFRA and FIP1L1 genes as a therapeutic target of imatinib in idiopathic hypereosinophilic syndrome. N Engl J Med 2003;348:1201-14.
12. Pardanani A, Reeder T. Imatinib therapy for hypereosinophilic syndrome and other eosinophilic disorders. Blood 2003;101: 3391-7. Epub 2002 Dec 27.